

## Does a Fibronectin and Aggrecan Complex Play a Role in Painful Vertebral Disks?

Jason M. Cuellar, MD, PhD, S. Raymond Golish, MD, PhD, Eric J. Leroux, MD, Merrill W. Reuter, MD, PhD, Eugene J. Carragee, MD, Lewis S. Hanna, PhD, Gaetano J. Scuderi, MD

**Objective:** To determine the presence of a fibronectin-aggrecan complex (FAC) in the disk space of persons with chronic low back pain as relates to provocative diskography.

**Design:** A single-center prospective consecutive case series.

**Setting:** A single private practice setting.

**Patients:** Thirty-seven patients with symptomatic degenerative disk disease of the cervical, thoracic, or lumbar spine undergoing provocative diskography to identify a source of pain.

**Methods:** Diskographic lavage for analysis was simultaneously performed at each disk level injected during diskography.

**Main Outcome Measures:** Visual analog scale (VAS) pain scores, Pfirrmann magnetic resonance imaging grade, and biochemical analysis of disk material were statistically analyzed.

**Results:** A total of 105 levels in 37 patients had a complete set of data (mean age  $43.2 \pm 11.9$  years; 15 male/22 female). The FAC was present in 43 of 108 levels and in at least one level in 25 of 37 patients. The Pfirrmann magnetic resonance imaging grade did not differ between complex-positive and negative levels ( $P = .125$ ), nor did the intraoperative VAS (IO-VAS) score for pain by level ( $P = .206$ ). A significant but loose correlation was found between Pfirrmann grade and IO-VAS ( $R^2 = 0.4$ ,  $P < .001$ ), but no significant correlation was found between VAS or IO-VAS and complex concentration ( $R^2 = 0.08$ ,  $P = .11$  and  $R^2 = 0.003$ ,  $P = .5$ ).

**Conclusions:** The FAC was identified in some painful disks by diskography. There was no significant correlation between the Pfirrmann grade or pre/intraoperative pain scores during diskography and complex concentrations within the disk measured by disk lavage.

PM R 2013;5:297-302

### INTRODUCTION

Debilitating low back pain (LBP) is a ubiquitous problem in industrialized countries and is associated with enormous morbidity and costs that continue to increase [1]. Although surgical treatment of axial LBP allows some patients to return to their normal activities of daily living, it continues to have great limitations and high failure rates [2-5]. The most challenging aspect of surgical treatment for LBP that health care providers face is selecting persons for whom surgical treatment is most likely to be efficacious. To that end, provocative diskography has been purported as beneficial [6]. Diskography has been used as an adjunct to magnetic resonance imaging (MRI), which is commonly used by physicians to help identify an underlying source of back pain; however, studies suggest that diskography and MRI are at best modestly predictive of outcomes after interventions directed at suspected "diskogenic" pain [6]. Moreover, recent work has cast a shadow on the use of diskography because accelerated degeneration and increased morbidity have been described [7].

A potential molecular marker of connective tissue (ie, intervertebral disk) degeneration that is correlated with the painful state causing radiculopathy from nerve root irritation in persons with degenerative diseases of the spine has been identified [8-10]. Moreover, this marker is predictive of functional improvement after a lumbar epidural steroid injection is

**J.M.C.** Department of Orthopaedic Surgery, NYU Hospital for Joint Diseases, New York, NY  
Disclosure outside this publication: consultancy, Cytonics Corp., Nevro Corp.; stock/stock options, Cytonics Corp., Nevro Corp.

**S.R.G.** Department of Orthopaedic Surgery, Stanford University, Palo Alto, CA  
Disclosure outside this publication: consultancy, Cytonics Corp.

**E.J.L.** Department of Orthopaedic Surgery, Stanford Medical School, Redwood City, CA.  
Address correspondence to: E.J.L.; e-mail: gscuderi@stanford.edu  
Disclosure: nothing to disclose

**M.W.R.** Private Practice, Lake Worth, FL  
Disclosure outside this publication: stock/stock options, Cytonics Corp.

**E.J.C.** Department of Orthopaedic Surgery, Stanford University, Palo Alto, CA  
Disclosure outside this publication: consultancy, Kaiser Permanente; expert medical legal testimony; grants/grants pending, AO Spine, OREF; other, direct funds received, *The Spine Journal*, editor-in-chief

**L.S.H.** Cytonics Inc., Jupiter, FL  
Disclosure outside this publication: stock/stock options, Cytonics Corp.

**G.J.S.** Department of Orthopaedic Surgery Stanford University, 450 Broadway St, MC 6342, Redwood City, CA 94063-6342. Address correspondence to: G.J.S.; e-mail: scudermid@aol.com  
Disclosure outside this publication: consultancy, Cytonics Corp.

Peer reviewers and all others who control content have no relevant financial relationships to disclose.

Submitted for publication May 14, 2012; accepted January 2, 2013.

administered. In the present study, we sought to identify the presence of this fibronectin-aggregan complex (FAC) in persons with chronic back pain syndromes.

Protein biomarkers associated with lumbar disk disease have been studied as diagnostic indicators and therapeutic targets. A complex molecular and cellular cascade of disk degeneration is being elucidated, which involves inflammatory mediators (eg, cytokines, nitric oxide, and signal transduction pathways), structural proteins and their degradation fragments (eg, fibronectin, aggregan, and collagens), and proteases/protease inhibitors (eg, matrix metalloproteinases and aggreganases) [11-15]. Numerous disease-modifying therapies have been proposed to intervene in this cascade, including antibody [16], stem cell [11], and gene [17] therapies, but their efficacy remains unproven.

The relationship among inflammatory cytokines and structural matrix proteins such as aggregan and fibronectin in the pathophysiology of degenerative joint diseases, although well established, continues to be clarified. Inflammatory cytokines are associated with fibronectin and its fragments in degenerative disease of the intervertebral disk [18] and synovial joints [19]. Aggregan and its fragments also have been implicated in degenerative disease of the intervertebral disk [20], as have aggreganases [21] and tissue inhibitors of metalloproteinases [22].

In synovial joints, aggregan cleavage is associated with fibronectin fragments [19]. Furthermore, there is apparent cross-immunoreactivity between interferon-gamma and the complex of fibronectin and aggregan in some commercial antibodies [9]. Moreover, it was recently reported that lavage fluid from the epidural space that demonstrates the presence of the FAC is significantly correlated with pain relief after epidural steroid injections for the treatment of radiculopathy with herniated nucleus pulposus [23]. These observations suggest a possible role for FAC in the pathophysiology of connective tissue degeneration and may aid in the selection of disks to treat in persons with LBP. To further elucidate the role of FAC in persons with painful degenerative disk disease, a comprehensive study including follow-up of persons with chronic LBP (CLBP) in whom the FAC is identified in select disks needs to be undertaken.

We measured levels of this protein complex in the disk spaces of patients undergoing lumbar diskography for CLBP refractory to conservative treatment. Our objective was to determine whether this marker was present in all degenerative disks or identified only in select disks, such as those with high-grade degeneration.

## MATERIALS AND METHODS

### Subjects

Independent Institutional Review Board approval was obtained (Sterling, Inc., Atlanta, GA), and all patients provided

informed consent for study participation. Patients considered candidates for provocative diskography were between 21 and 75 years of age with a history of CLBP of 6 months or longer and had failed to reasonably improve with treatment, including nonsteroidal anti-inflammatory drugs, activity modification, and/or physical therapy. The patients were identified among 119 consecutive patients who were offered diskography for the evaluation of their chronic pain (study group). This cohort was drawn from the practice of a single board-certified orthopedic spine surgeon (G.J.S.) from January 2008 to May 2009.

Patients with a history of oral or injected corticosteroid medication use within a 3-month period before diskography, patients who had previously undergone diskography, and patients with chronic medical conditions associated with metabolic or inflammatory disorders (eg, insulin-dependent diabetes mellitus, severe coronary artery disease, or rheumatic or autoimmune diseases) were excluded from the study.

Demographic information, including gender, age, insurance, work status, and reported pain on a 0 to 10 visual analog scale (VAS), was obtained before the procedure. Provocative diskography, with recording of annular disruption, pain intensity during the procedure (ie, intraoperative VAS [IO-VAS] score), and concordance for each disk injected was performed by an experienced diskographer (M.R.). A blinded analysis of MRI was performed by an experienced, independent examiner (G.J.S.), with each injected disk level classified according to the Pfirrmann grading scale (Table 1) [24].

### Sample Acquisition, Storage, and Preparation

At the time of diskography, lavage was undertaken before injection as previously described [10,25]. In summary, the patient was positioned prone on a radiolucent table, and monitored anesthesia was induced. After preparation with 1% povidone iodine, a 22-gauge spinal needle was placed into the disk space with the use of C-arm fluoroscopy in multiple planes. Lavage was undertaken by injection and aspiration of 1-2 mL of 0.9% normal saline solution without preservative with use of a 3-mL syringe. The lavage fluid was

**Table 1.** Breakdown of study disks by Pfirrmann grade

Pfirrmann Grade	Description of Grade	No. (%) of Disks
I	Homogeneous, bright white	13 (12.4)
II	Inhomogeneous with or without horizontal bands	34 (32.4)
III	Inhomogeneous, gray	31 (29.5)
IV	Inhomogeneous, gray to black	18 (17.1)
V	Inhomogeneous, black, collapsed disc space	9 (8.6)
Grand total		105 (100)

**Table 2.** Study population

Characteristic	N or Mean ± SD
Males	15
Females	22
Age	43.2 ± 11.9
VAS	8.0 ± 1.3
IO-VAS	4.3 ± 3.3

IO-VAS = intraoperative visual analog score for pain; VAS = visual analog score for pain (preoperative).

aliquoted into a sterile polypropylene tube and frozen at -80°C until the time of sample analysis [26]. At the time of analysis, each patient sample was thawed to room temperature, clarified by centrifugation at 5000g, and filtered using a 0.45-µm low-protein binding filter. The collected filtrate was immediately assayed as described in the next section.

### Sandwich Enzyme-Linked Immunosorbent Assay Analysis

A heterogeneous sandwich enzyme-linked immunosorbent assay (ELISA) was developed and validated with a previous series of patients [9]. This assay detects a protein complex of fibronectin and the aggrecan G3 domain (ie, FAC). A heterogeneous ELISA was developed for detection of FAC with the use of an antibody against one protein for capture and against the other protein for detection. Assay conditions were optimized to minimize background signal, and individual proteins were used as negative controls.

In summary, an antiaggrecan G3 domain antibody (Santa Cruz Biotechnology, Santa Cruz, CA) in phosphate-buffered saline/Tween 20/thimerosal was used to coat a 96-well microplate. The plate was treated with bovine serum albumin in the same buffer overnight at 4°C to block excess binding sites, then washed with 6 washes of phosphate-buffered saline/Tween 20/thimerosal. The centrifuged and filtered sample was aliquoted at 3 serial dilutions in triplicate into the microplate and incubated for 1 hour to facilitate binding of the complex to the immobilized antibody. After washing 6 times with the wash buffer, an antifibronectin antibody labeled with horseradish peroxidase (US Biological, Swampscott, MA) was added and incubated for 1 hour. After 6

**Table 3.** Sample site and presence of complex

Level	No. of Samples	Average FAC Concentration ± SD
L1/2	6	0.010 ± 0.005
L2/3	12	0.058 ± 0.132
L3/4	29	0.070 ± 0.153
L4/5	31	0.100 ± 0.209
L5/S1	27	0.150 ± 0.442
Grand total	105	0.095 ± 0.270

FAC = fibronectin-aggrecan complex (concentration is measured in optical density units); L = lumbar; S = sacral.

**Table 4.** FAC concentration at different Pfirrmann scores

Pfirrmann	Female	Male	Combined
1	0.060 ± 0.121	0.055 ± 0.082	0.058 ± 0.100
2	0.066 ± 0.166	0.034 ± 0.074	0.055 ± 0.140
3	0.148 ± 0.566	0.090 ± 0.180	0.120 ± 0.420
4	0.128 ± 0.260	0.232 ± 0.240	0.180 ± 0.249
5	0.072 ± 0.099	0.010 ± 0.016	0.046 ± 0.077
Grand total	0.103 ± 0.353	0.090 ± 0.167	0.095 ± 0.270

FAC = fibronectin-aggrecan complex (concentration is measured in optical density units).

washes, the 3,3',5,5'-tetramethylbenzidine (TMB) substrate was added and the reaction product was measured by optical density (OD) at 450-nm wavelength (therefore measurements are reported in relative OD units rather than an absolute concentration). Human fibronectin (BD Biosciences, San Jose, CA) at 10 µg/mL concentration was used as a negative control.

### Statistical Methods

**Data Analysis.** Least-squares correlation regression analyses were used to quantify a correlation between VAS and IO-VAS and protein complex concentration measured with ELISA and Pfirrmann grade for each disk. The *t*-test was used for the comparison of 2 means. Univariate analysis of variance was used to compare 3 or more means, such as comparing mean FAC concentration by Pfirrmann score.

### RESULTS

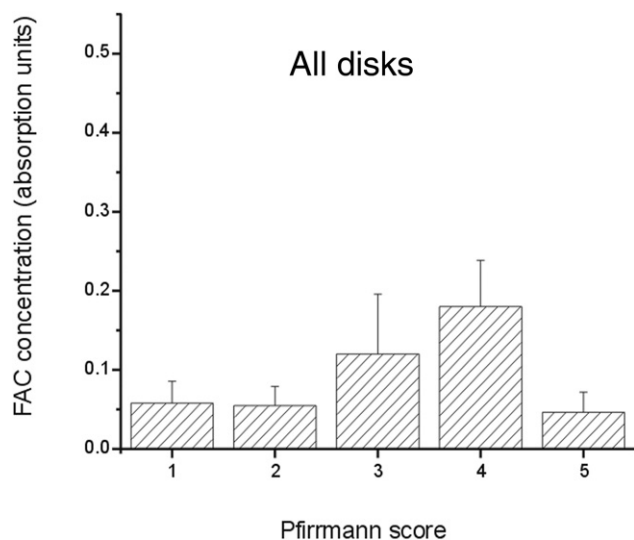
Thirty-seven patients (15 men and 22 women with a mean age of 43 ± 12 years) were enrolled from January 2008 to May 2009 (Table 2). Tables 1 and 3 provide a breakdown of patient population by Pfirrmann grade and intervertebral disk level. Use of diskography was determined by the physician and performed in a range of 1 to 4 disks in each patient. The FAC was present in 43 of 105 disks and in at least one level in 25 of 37 patients. The FAC concentration from disks with different Pfirrmann scores are presented in Table 4. The Pfirrmann MRI grade did not differ between FAC-positive and FAC-negative levels (*P* = .125), nor did the IO-VAS differ by level (*P* = .206). A trend was

**Table 5.** FAC positivity by Pfirrmann grouping (high 3-5, low 1-2)\*

	FAC-Negative	FAC-Positive	Grand Total
Pfirrmann 3-5	32	26	58
Pfirrmann 1-2	30	17	47
Grand total	62	43	105

FAC = fibronectin-aggrecan complex.

\*There was a trend for greater FAC concentration in disks with a Pfirrmann score of 3 or 4, but this finding did not reach statistical significance (*P* = .09).



**Figure 1.** The average concentration (reported as optical density units) of the fibronectin-aggregan complex (FAC) is plotted in relative absorption units measured by custom enzyme-linked immunosorbent assay for each group of disks, organized by Pfirrmann grade (error bars represent standard error of the mean). This figure reports averages for all study disks. There was a trend for greater FAC concentration in disks with a Pfirrmann score of 3 or 4, but this finding did not reach statistical significance ( $P = .09$ ) when all disks were included in the analysis.

noted for greater FAC concentration in disks with a Pfirrmann score of 3 or 4, but this trend did not reach statistical significance ( $P = .09$ ; Table 5 and Figures 1 and 2) when all disks were included in the analysis. FAC-positive disks with a Pfirrmann score of 3 or 4 had an average greater FAC level compared with FAC-positive disks with a Pfirrmann score of 1, 2, or 5 (mean 0.32 versus 0.14;  $P < .05$ ). A statistically significant ( $P < .001$ ) but weak correlation ( $R^2 = 0.4$ ) was found between Pfirrmann grade and IO-VAS, but no significant correlation was found between VAS or IO-VAS and complex concentration ( $R^2 = 0.08$ ,  $P = .11$ , and  $R^2 = 0.03$ ,  $P = .07$ , respectively).

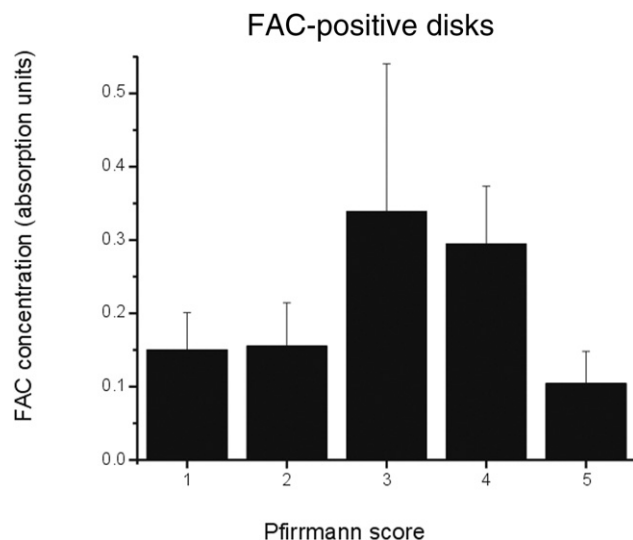
## DISCUSSION

The present study demonstrates that FAC does exhibit a presence in disk lavage fluid of a majority of patients with CLBP, as predicted by recent studies [8,9,26]. However, there was no significant correlation with prediskography or intradiskography pain scores or Pfirrmann MRI grades to the presence of the protein complex. This finding differs from that of a previous study in which patients with suspected spinal nerve root irritation were examined with use of epidural lavage [23] and could reflect either a difference between the intradiskal space compared with the epidural space or the patient population. The differing finding also might reflect

the inherent challenges in the interpretation of provocative diskography, a modality well known to be problematic in its clinical reliability in patients with CLBP [27-29].

The observation in the present study that FAC was not detected in all degenerative disks is contrary to growing evidence that inflammatory cytokines are associated with fibronectin, fibronectin fragments, aggrecanases, and aggrecan fragmentation in degenerative disease of the intervertebral disk [13,14,18]. Several possible explanations exist for the large percentage of degenerative disks with a negative FAC test. Performing diskography at the wrong level is one possibility. It has been shown that each disk annulus and endplate receive multisegmental innervation from both the recurrent branch of the ventral primary ramus of the spinal nerve (sinuvertebral nerve) and the paravertebral sympathetic trunk [30-32]. For example, studies in animals have demonstrated that the L5-L6 disk is innervated via the sinuvertebral nerves from dorsal root ganglia (DRG) L3-L5 and via the sympathetic trunk by DRG T13-L2 [33-35]. Contralateral DRG involvement also occurs via both pathways [36,37]. These observations may explain the relatively diffuse spread of axial spinal pain and difficulty in the accurate localization of pain and the pain-generating disk.

Another distinct possibility is dilution of the small amount of FAC to levels below the assay's level of detection, which might occur because of the small aspirate volumes achieved



**Figure 2.** The average concentration (reported as optical density units) of the fibronectin-aggregan complex (FAC) is plotted in relative absorption units measured by custom enzyme-linked immunosorbent assay for each group of disks, organized by Pfirrmann grade (error bars represent standard error of the mean). This figure reports averages for only the disks that were positive for FAC. FAC-positive disks with a Pfirrmann score of 3 or 4 had an average greater FAC level compared with positive disks with a Pfirrmann score of 1, 2, or 5 (mean 0.32 versus 0.14;  $P < .05$ ).

during diskography, a factor that is difficult to avoid with the current technique. Furthermore, it is possible that severely degenerated disks are “burned out,” that is, desiccated to such an extent that minimal levels of collagen and byproducts of disk degeneration remain. The present study provides some support for this explanation, given the observed trend of greater FAC concentrations in Pfirrmann 3-4 disks and lower levels in Pfirrmann 5 disks.

The present investigation has some noteworthy shortcomings. The diskographic lavage technique may result in a small volume of aspirate after injection/aspiration of a variable amount of diluents [25]. This factor, in conjunction with the biology of the disease process, may result in a wide range of concentrations for biomarkers assayed, requiring a sensitive assay and inducing floor or ceiling effects typical of immunoassays [8]. In the present study, these issues are addressed with the use of a sensitive heterogeneous ELISA, although the lack of a synthesizable positive control makes absolute quantification impossible. A reference standard and positive control for the FAC must be synthesized in large scale to generate a standard curve by which the OD (at 450-nm optical wavelength) can be converted to an absolute concentration. In addition, different values for the limit of detection would yield different estimates of positive versus negative test values. Although there was a variable amount of time from sample collection to analysis that was unavoidable, our laboratory has performed stability studies demonstrating no decrement in ELISA signal at up to 1 year.

Furthermore, the present study likely had an inclusion bias in that all of the subjects were scheduled for provocative diskography, and thus an uncertainty in the diagnosis may have been more likely than in a study conducted with surgical patients only. The patients in this study likely represent the cohort of patients that is most difficult to treat—those with CLBP of uncertain origin.

## CONCLUSION

A novel protein-protein complex, the FAC, was identified in some painful disks by diskography. Although a trend toward greater FAC levels in Pfirrmann 3 and 4 grade disks was noted, no significant correlation between VAS or IO-VAS and complex concentration was found. A biomarker present in specific disks in patients experiencing debilitating CLBP could improve our understanding of the pathophysiology of CLBP and lead to vastly improved therapeutic decision making and possibly even more targeted therapeutics, although additional investigation is needed to reach this goal.

## ACKNOWLEDGMENTS

We thank Katie Dent and Naruewan Woolf for their assistance in the sample processing.

## REFERENCES

1. Deyo RA, Gray DT, Kreuter W, Mirza S, Martin BI. United States trends in lumbar fusion surgery for degenerative conditions. *Spine* 2005;30:1441-1445; discussion 6-7.
2. Carragee E. Surgical treatment of lumbar disk disorders. *JAMA* 2006;296:2485-2487.
3. Fairbank J, Frost H, Wilson-MacDonald J, Yu LM, Barker K, Collins R. Randomised controlled trial to compare surgical stabilisation of the lumbar spine with an intensive rehabilitation programme for patients with chronic low back pain: The MRC spine stabilisation trial. *BMJ* 2005;330:1233.
4. Brox JI, Sorensen R, Friis A, et al. Randomized clinical trial of lumbar instrumented fusion and cognitive intervention and exercises in patients with chronic low back pain and disc degeneration. *Spine* 2003;28:1913-1921.
5. Fritzell P, Hagg O, Wessberg P, Nordwall A. 2001 Volvo Award Winner in Clinical Studies: Lumbar fusion versus nonsurgical treatment for chronic low back pain: A multicenter randomized controlled trial from the Swedish Lumbar Spine Study Group. *Spine* 2001;26:2521-2532; discussion 32-34.
6. Derby R, Kim BJ, Lee SH, Chen Y, Seo KS, Aprill C. Comparison of discographic findings in asymptomatic subject discs and the negative discs of chronic LBP patients: Can discography distinguish asymptomatic discs among morphologically abnormal discs? *Spine J* 2005;5:389-394.
7. Carragee EJ, Don AS, Hurwitz EL, Cuellar JM, Carrino J, Herzog R. 2009 ISSLS Prize Winner: Does discography cause accelerated progression of degeneration changes in the lumbar disc: A ten-year matched cohort study. *Spine (Phila Pa 1976)* 2009;34:2338-2345.
8. Scuderi GJ, Cuellar JM, Cuellar VG, Yeomans DC, Carragee EJ, Angst MS. Epidural interferon gamma-immunoreactivity: A biomarker for lumbar nerve root irritation. *Spine (Phila Pa 1976)* 2009;34:2311-2317.
9. Scuderi GJ, Woolf N, Dent K, et al. Identification of a complex between fibronectin and aggrecan G3 domain in synovial fluid of patients with painful meniscal pathology. *Clin Biochem* 2010;43:808-814.
10. Cuellar JM, Golish SR, Reuter MW, et al. Cytokine evaluation in individuals with low back pain using discographic lavage. *Spine J* 2010;10:212-218.
11. Anderson DG, Risbud MV, Shapiro IM, Vaccaro AR, Albert TJ. Cell-based therapy for disc repair. *Spine J* 2005;5(6 suppl):2975-3035.
12. Freemont AJ, Watkins A, Le Maitre C, Jeziorska M, Hoyland JA. Current understanding of cellular and molecular events in intervertebral disc degeneration: Implications for therapy. *J Pathol* 2002;196:374-379.
13. Walker MH, Anderson DG. Molecular basis of intervertebral disc degeneration. *Spine J* 2004;4(6 suppl):158S-166S.
14. Hadjipavlou AG, Tzermiadianos MN, Bogduk N, Zindrick MR. The pathophysiology of disc degeneration: A critical review. *J Bone Joint Surg Br* 2008;90:1261-1270.
15. Kang JD, Georgescu HI, McIntyre-Larkin L, Stefanovic-Racic M, Donaldson WF 3rd, Evans CH. Herniated lumbar intervertebral discs spontaneously produce matrix metalloproteinases, nitric oxide, interleukin-6, and prostaglandin E2. *Spine* 1996;21:271-277.
16. Korhonen T, Karppinen J, Paimela L, et al. The treatment of disc herniation-induced sciatica with infliximab: Results of a randomized, controlled, 3-month follow-up study. *Spine* 2005;30:2724-2728.
17. Vadala G, Sowa GA, Kang JD. Gene therapy for disc degeneration. *Expert Opin Biol Ther* 2007;7:185-196.
18. Anderson DG, Li X, Balian G. A fibronectin fragment alters the metabolism by rabbit intervertebral disc cells in vitro. *Spine (Phila Pa 1976)* 2005;30:1242-1246.

19. Homandberg GA, Hui F, Wen C, et al. Fibronectin-fragment-induced cartilage chondrolysis is associated with release of catabolic cytokines. *Biochem J* 1997;321(pt 3):751-757.
20. Patel KP, Sandy JD, Akeda K, et al. Aggrecanases and aggrecanase-generated fragments in the human intervertebral disc at early and advanced stages of disc degeneration. *Spine (Phila Pa 1976)* 2007;32:2596-2603.
21. Le Maitre CL, Freemont AJ, Hoyland JA. Localization of degradative enzymes and their inhibitors in the degenerate human intervertebral disc. *J Pathol* 2004;204:47-54.
22. Pockert AJ, Richardson SM, Le Maitre CL, et al. Modified expression of the ADAMTS enzymes and tissue inhibitor of metalloproteinases 3 during human intervertebral disc degeneration. *Arthritis Rheum* 2009;60:482-491.
23. Golish SR, Hanna LS, Bowser RP, Montesano PX, Carragee EJ, Scuderi GJ. Outcome of lumbar epidural steroid injection is predicted by assay of a complex of fibronectin and aggrecan from epidural lavage. *Spine (Phila Pa 1976)* 2011;36:1464-1469.
24. Pfirrmann CW, Metzdorf A, Zanetti M, Hodler J, Boos N. Magnetic resonance classification of lumbar intervertebral disc degeneration. *Spine* 2001;26:1873-1878.
25. Scuderi GJ, Brusovanik GV, Anderson DG, et al. Cytokine assay of the epidural space lavage in patients with lumbar intervertebral disk herniation and radiculopathy. *J Spinal Disord Tech* 2006;19:266-269.
26. Cuellar JM, Scuderi GJ, Cuellar VG, Golish SR, Yeomans DC. Diagnostic utility of cytokine biomarkers in the evaluation of acute knee pain. *J Bone Joint Surg* 2009;91:2313-2320.
27. Carragee EJ, Alamin TF, Carragee JM. Low-pressure positive discography in subjects asymptomatic of significant low back pain illness. *Spine* 2006;31:505-509.
28. Carragee EJ, Tanner CM, Yang B, Brito JL, Truong T. False-positive findings on lumbar discography. Reliability of subjective concordance assessment during provocative disc injection. *Spine* 1999;24:2542-2547.
29. Carragee EJ, Tanner CM, Khurana S, et al. The rates of false-positive lumbar discography in select patients without low back symptoms. *Spine* 2000;25:1373-1380; discussion 1381.
30. Nakamura SI, Takahashi K, Takahashi Y, Yamagata M, Moriya H. The afferent pathways of discogenic low-back pain. Evaluation of L2 spinal nerve infiltration. *J Bone Joint Surg Br* 1996;78:606-612.
31. Nakamura S, Takahashi K, Takahashi Y, Morinaga T, Shimada Y, Moriya H. Origin of nerves supplying the posterior portion of lumbar intervertebral discs in rats. *Spine* 1996;21:917-924.
32. Fagan A, Moore R, Vernon Roberts B, Blumbergs P, Fraser R. ISSLS prize winner: The innervation of the intervertebral disc: A quantitative analysis. *Spine* 2003;28:2570-2576.
33. Takahashi Y, Chiba T, Kurokawa M, Aoki Y, Takahashi K, Yamagata M. Stereoscopic structure of sensory nerve fibers in the lumbar spine and related tissues. *Spine* 2003;28:871-880.
34. Aoki Y, Takahashi Y, Takahashi K, et al. Sensory innervation of the lateral portion of the lumbar intervertebral disc in rats. *Spine J* 2004;4:275-280.
35. Ozawa T, Aoki Y, Ohtori S, et al. The dorsal portion of the lumbar intervertebral disc is innervated primarily by small peptide-containing dorsal root ganglion neurons in rats. *Neurosci Lett* 2003;344:65-67.
36. Ohtori S, Takahashi K, Chiba T, Yamagata M, Sameda H, Moriya H. Sensory innervation of the dorsal portion of the lumbar intervertebral discs in rats. *Spine (Phila Pa 1976)* 2001;26:946-950.
37. Ohtori S, Takahashi Y, Takahashi K, et al. Sensory innervation of the dorsal portion of the lumbar intervertebral disc in rats. *Spine* 1999;24:2295-2299.

---

*This CME activity is designated for 1.0 AMA PRA Category 1 Credit™ and can be completed online at [me.aapmr.org](http://me.aapmr.org). Log on to [www.me.aapmr.org](http://www.me.aapmr.org), go to Lifelong Learning (CME) and select Journal-based CME from the drop down menu. This activity is FREE to AAPM&R members and \$25 for non-members.*

---

### CME Question

Intradiskal fibronectin-aggrecan complex (FAC) concentration weakly correlated with:

- a. level of lumbar disk sampled
- b. pre-diskography pain level
- c. advanced subject age
- d. degenerative disk grade

Answer online at [me.aapmr.org](http://me.aapmr.org)